

## **Case study**

### **Colon Cancer with Complete Pathological Response to only 1 Cycle of Capecitabine: Treatment Modification in the Perspective of Covid-19 Pandemic.**

#### **Abstract:**

Incidence of colorectal cancer has surged in the past few decades, currently it accounts for approximately 10% cancer related mortality. Upfront curative surgery is the main stay of treatment for localized disease followed by adjuvant chemotherapy for high-risk disease; however, neo adjuvant chemoradiation followed by surgery and chemotherapy is a standard treatment for rectal cancer. Here, we present a case of a young male aged 33 years with eight months' history of per rectal bleeding, associated with fever and weight loss who was later diagnosed as sigmoid colon adenocarcinoma. The patient managed to have only one cycle of neoadjuvant capecitabine, as his definitive surgery was delayed due to the rise in pandemic situation of Covid-19. Notably, follow up laparoscopic LAR specimen showed no residual disease, nevertheless, there was an eosinophilic abscess with a giant cell reaction and Ova of *Ascaris lumbricoides*, which seemingly contributed in achieving pathological complete response with minimal therapy.

**Keywords:** Colon Cancer, Covid-19 Pandemic, Capecitabine, Complete Pathological Response

## Introduction

Colorectal cancer is the fourth most common cause of cancer death in the world with 700000 patients dying of this disease every year [1]. Various risk factors have established contribution in colorectal cancer namely high body mass index, physical inactivity, dietary factors including low fiber diet, increased animal protein consumption, cigarette smoking, alcohol abuse, family history of colon cancer, oral contraceptive pill usage. Whereas, calcium, vitamin D, milk, dairy diets, and drugs such as aspirin and nonsteroidal anti-inflammatory have a protective effect [2]. There are reports on the association of colon cancer with microbiological as well as helminthic infections. A causal association with *Fusobacterium nucleatum* infection has been reported in colon cancer among patients of younger age group [3]. Blood flukes; *Schistosoma haematobium* and *mansoni* have been classified as group 1 carcinogens for colon and hepatocellular carcinoma, by International Agency for Research on Cancer [3]. Helminthic infections are also an important differential diagnostic consideration of colon cancer at their initial presentation. Apart from the causal association; helminthic infections have also been proposed to play a role in the activation of the immune response against tumors cells by molecular mimicry between tumor cells and surface antigens of some of the helminthic infections [4].

Upfront complete surgical resection with negative surgical margins is the definitive treatment option for localized and locally advanced colon cancer stages I-III, with adjuvant chemotherapy recommended in patients with high-risk features [5]. There is no role of neoadjuvant chemotherapy in the formerly mentioned group of patients with colon cancer [6].

We are reporting a case of clinically locally advanced *adenocarcinoma* of the recto-sigmoid region with only subtle pericolonic fat stranding, initially planned for definitive surgery but ended up receiving neoadjuvant, single-agent chemotherapy just to buy time and prevent possible progression during the Covid-19 pandemic.

## Case report:

A 33 years-old male with no known comorbid medical conditions presented with a history of bleeding per rectum for 8 months associated with constipation and pain in the right upper quadrant of the abdomen. One month prior to presentation, the patient started experiencing low-grade fever associated with generalized weakness and 4.5 lbs of weight loss in the same month. His baseline CEA was 14.2 ng/ml. MRI abdomen and pelvis with contrast revealed asymmetrical thickening of the sigmoid colon (as shown in Figure 1) with no pericolic lymph nodes and there were few sigmoid diverticuli. The patient underwent a colonoscopy which revealed a 5 cm polypoid, ulcerated tumor, about 12 cm from the anal verge at the recto-sigmoid junction, a granular mucosa with patchy small ulcers in the sigmoid colon and descending colon (as shown in Figure 2). Histopathology exhibited moderately differentiated adenocarcinoma arising in a background of tubular adenoma in the recto-sigmoid region, tubulovillous adenoma in the sigmoid region, and normal colonic mucosa with preserved crypt architecture in the descending colon (as shown in Figure 3). In addition, the MRI pelvis showed recto-sigmoid thickening extending to a length of 3 cm with subtle adjacent fat stranding, making it an early T3 disease. A staging CT scan of the chest and abdomen revealed no hepatic, pulmonary, or osseous metastasis. His disease was staged as cT3N0M0, Stage IIA. In view of above, a multidisciplinary team meeting recommended upfront surgery; however, because of the Covid-19 pandemic situation, surgery seemed to lag. Therefore, the patient was prescribed neoadjuvant capecitabine (1000 mg/m<sup>2</sup>). He managed to have 1 complete cycle of oral capecitabine for 3 weeks with 2 weeks on and one week off regimen, followed by only 1 week of the same dose for 2nd cycle before undergoing laparoscopic low anterior resection with covering ileostomy. Histopathology of the surgical specimen labeled post-chemo changes in the specimen and acellular pool of mucin in bowel wall with no residual tumor and 18/18 lymph nodes free of tumor (ypTON0). There was also one center of eosinophilic abscess, giant cell reaction, and ova of *Ascaris lumbricoides* (as shown in Figure 4). Post-surgery, his CEA was 1.78 ng/ml. Histopathology specimens, both on diagnosis as well as surgical pathology; were reviewed in multidisciplinary tumor board and patient is on follow up since May 2020 with no evidence of disease recurrence.

**Consent and approval from Institutional review board.**

This case report is being published after approval from ***The Institutional Review Board of Shaukat Khanum Memorial Cancer Hospital and Research Center (SKMCH&RC) Lahore*** for publication. The information obtained in the clinical records of the institution or directly from the patient will be kept under maximum confidentiality, therefore, no data will be published that could compromise the privacy of the patients.

**Consent for publication.**

Written informed consent for publication was obtained from the patient, our institutional consent form is available from the corresponding author on reasonable request.

UNDER PEER REVIEW

## Discussion:

In summary, our patient was a young man, who presented with bleeding per rectum, fever, and weight loss. He was diagnosed as moderately differentiated adenocarcinoma of the recto-sigmoid junction and on imaging; it was a localized disease with subtle pericolonic fat stranding. Because of the prevailing Covid-19 pandemic situation, he received one and a half cycles of neoadjuvant capecitabine before getting a definitive laparoscopic low anterior resection with no residual tumor; however, there was an incidental finding of eosinophilic abscess focus containing giant cell reaction and ova of *Ascaris lumbricoides*.

As stated earlier, the definitive treatment for localized and locally advanced colon cancer is surgical resection with negative surgical margins, while adjuvant chemotherapy is considered for patients with high-risk features. There is no proven role of neoadjuvant chemotherapy in the patient population with localized disease. However, there are small series and a pilot phase randomized clinical study on the role of neoadjuvant chemotherapy in clinically and locally advanced, medically operable, colorectal cancer with significant downstaging of the tumor along with acceptable perioperative mortality and toxicity [7]. According to a study, a group of 47 patients with locally advanced; T3/T4a-b disease, when treated with 3 cycles of neoadjuvant capecitabine and oxaliplatin combination achieved a complete radiological response rate, in 66% of patients and a complete pathological response in 2% of the patient population [8]. Based on this data, ACS, SSO, and NCCN guidelines during the Covid-19 pandemic situation recommend, capecitabine-based combination therapy or oral capecitabine alone with intent to defer surgery until progression or until there is an emergency indication for surgery [9].

Since we know, *Ascaris lumbricoides* infestation is the most common infestation worldwide [10], frequently leading to an infestation of the small bowel and right side of the colon, and is an important differential diagnosis of the acute abdomen [11]. Although colonic infestation with *Strongyloides stercoralis* has a causal association with colorectal cancer, yet, no causal relationship exists between colorectal cancer and *Ascaris lumbricoides* infestation [12]. Upon further literature review, it appeared that apart from meager causal association with colorectal cancer by virtue of tumor-promoting effects in colitis-associated colorectal cancer [13], certain helminthic infections have been found to be

activating tumor surveillance through antigenic similarity between surface antigens of helminths and tumor cells leading to activation of Natural Killer (NK) cells, CD4+/CD8+ cells, macrophages and dendritic cells with increased NADPH oxidase activity [4]. In acute settings, immune response to *Ascaris lumbricoides* is mediated by type 2 helper T-cells, leading to high levels of immunoglobulin E and eosinophilia facilitating resistance to infection and expulsion of the organism [14]. This can further be supported by the fact that allergic cancer patients show a favorable response to treatment and decreased prevalence of certain cancer subtypes in areas of the world where helminthic infections are widely prevalent. [15].

## CONCLUSION

Neoadjuvant capecitabine can lead to complete pathological response and can be an alternative strategy to definitive upfront surgery to buy time in the critical public health situation of the Covid-19 pandemic. Having said that, it is far less likely for only one cycle of capecitabine to have led to complete pathological response. *Ascaris lumbricoides* infestation has no proven carcinogenic association with colorectal cancer, however, the immunologic response to acute infestation with *Ascaris lumbricoides* may play a role in the cure of early-stage colorectal cancer.

## COMPETING INTERESTS DISCLAIMER:

Authors have declared that no competing interests exist. The products used for this research are commonly and predominantly used products in our area of research and country. There is absolutely no conflict of interest between the authors and producers of the products because we do not intend to use these products as an avenue for any litigation but for the advancement of knowledge. Also, the research was not funded by the producing company rather it was funded by personal efforts of the authors.

## References

1. Brody H: Colorectal cancer. Nature. 2015, 521:1. 10.1038/521S1a
2. Shang FM, Liu HL: Fusobacterium nucleatum and colorectal cancer: A review. World J Gastrointest Oncol. 2018, 10:71-81. 10.4251/wjgo.v10.i3.71

3. IARC Working Group on the Evaluation of Carcinogenic Risks to Humans: Biological agents. Volume 100 B. A review of human carcinogens. IARC Monogr Eval Carcinog Risks Hum. 2012:1-441.
4. Blanca E. Callejas, Diana Martínez-Saucedo, Luis I: Terrazas; Parasites as negative regulators of cancer. Biosci Rep 31 October. 2018, 38:20180935. 10.1042/BSR20180935
5. Haller DG, Catalano PJ, Macdonald JS, et al.: Phase III study of fluorouracil, leucovorin, and levamisole in high-risk stage II and III colon cancer: final report of Intergroup 0089. J Clin Oncol. 2005, 23:8671-8678. 10.1200/JCO.2004.00.5686
6. V, Glimelius B, Haustermans K, et al.: ESMO Consensus Guidelines for management of patients with colon and rectal cancer. a personalized approach to clinical decision making. Ann Oncol. 2012, 23:2479-516. 10.1093/annonc/mds236
7. Foxtrot Collaborative Group: Feasibility of preoperative chemotherapy for locally advanced, operable colon cancer: the pilot phase of a randomised controlled trial. Lancet Oncol. 2012, 13:1152-1160. 10.1016/S1470-2045(12)70348-0
8. Liu F, Yang L, Wu Y, et al.: CapOX as neoadjuvant chemotherapy for locally advanced operable colon cancer patients: a prospective single-arm phase II trial. Chin J Cancer Res. 2016, 28:589-597. 10.21147/j.issn.1000-9604.2016.06.05
9. Deo SVS, Kumar S, Kumar N, et al.: Guiding Principles for Cancer Surgery during the COVID-19 Pandemic [published online ahead of print, 2020 May 6]. Indian J Surg Oncol. 2020, 1:8. 10.1007/s13193-020-01082-x
10. Bethony J, Brooker S, Albonico M, et al.: Soil-transmitted helminth infections: ascariasis, trichuriasis, and hookworm. Lancet. 2006, 6:1521-32. 10.1016/S0140-6736(06)68653-
11. Jourdan PM, Lamberton PHL, Fenwick A, Addiss DG: Soil-transmitted helminth infections. Lancet. 2018, 391:252-265. 10.1016/S0140-6736(17)31930-
12. Catalano C, Aron J, Bansal R, Leytin A.: Colorectal Cancer Associated with *Strongyloides stercoralis* Colitis. ACG Case Rep J. 2017, 30:1. 10.14309/crj.2017.104.
13. Pastille E, Frede A, McSorley HJ, et al.: Intestinal helminth infection drives carcinogenesis in colitis-associated colon cancer. PLoS Pathog. 2017, 13:1006649.

14. Finkelman FD, Shea-Donohue T, Goldhill J, et al. Cytokine regulation of host defense against parasitic gastrointestinal nematodes: lessons from studies with rodent models. *Annu Rev Immunol.* 1997, 15:505-533. 10.1146/annurev.immunol.15.1.505.
15. Pompei R, Lampis G, Ingianni A, et al.: Allergy and tumour outcome after primary cancer therapy. *Int Arch Allergy Immunol.* 2004, 133:174-8. 10.1159/000076624

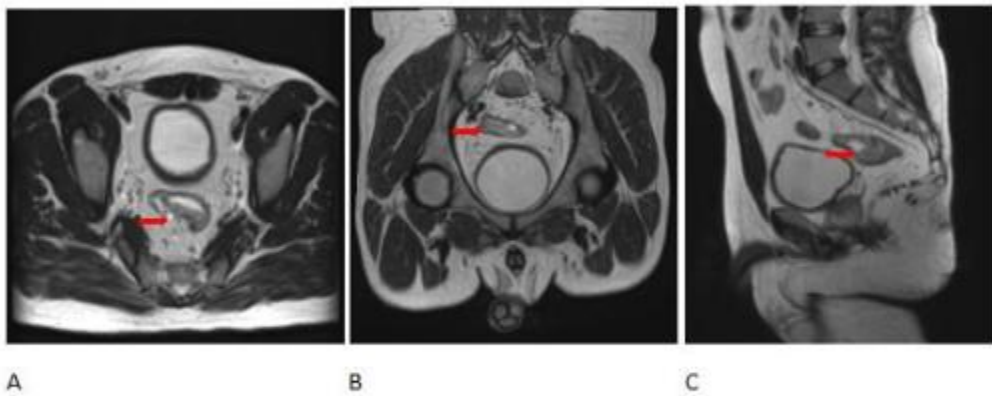


Figure 1: Axial (A), Coronal (B), Sagittal (C) T2 images showing asymmetric thickening of recto-sigmoid junction (Red Arrows).



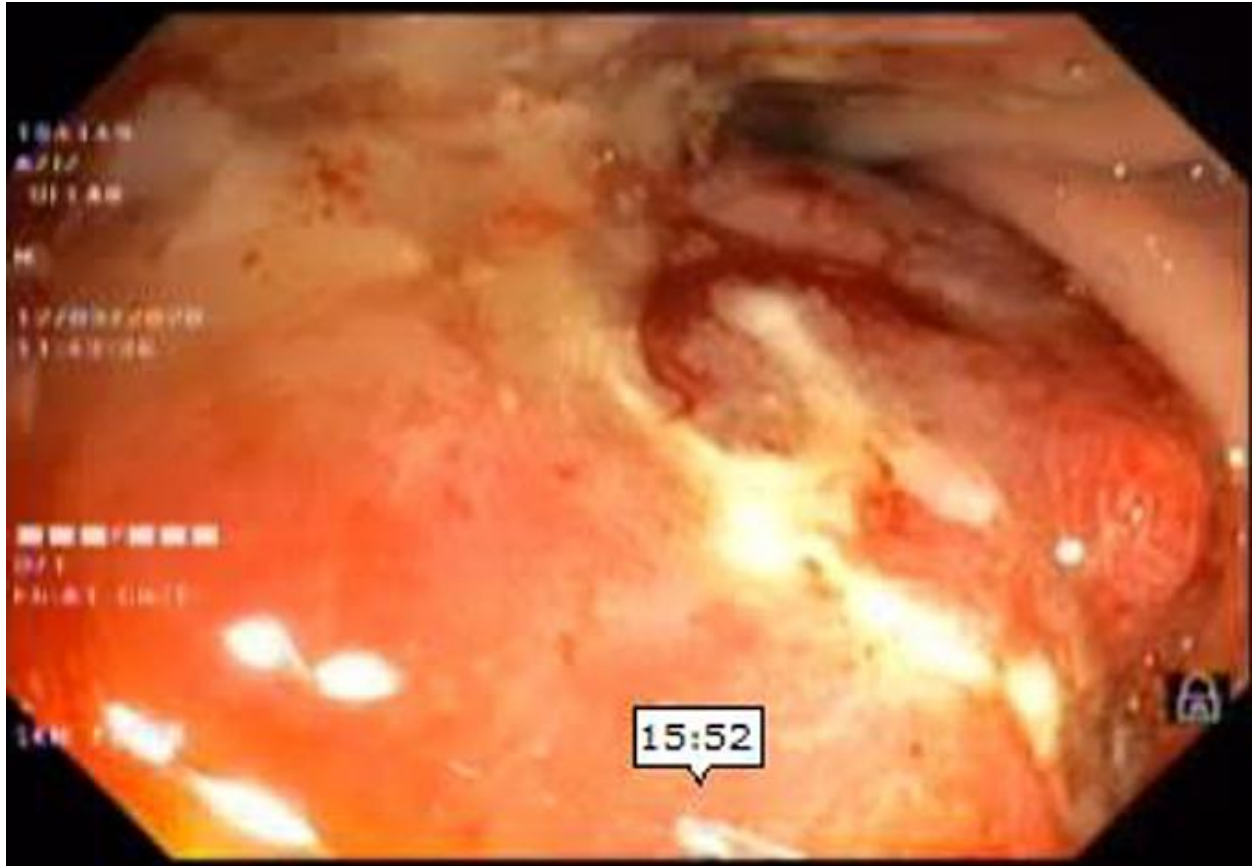


Figure 2: Colonoscopy image of 5 cm polypoid ulcerated tumor about 12 cm from the anal verge, at the recto-sigmoid junctio

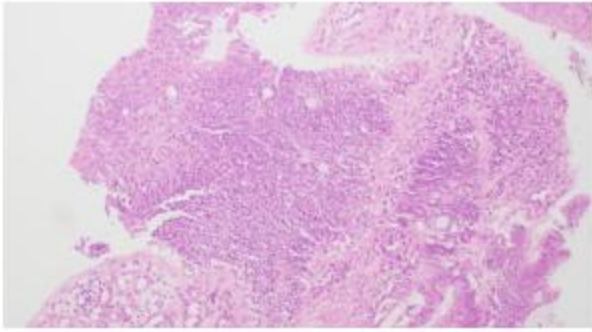


Figure 3. (A)

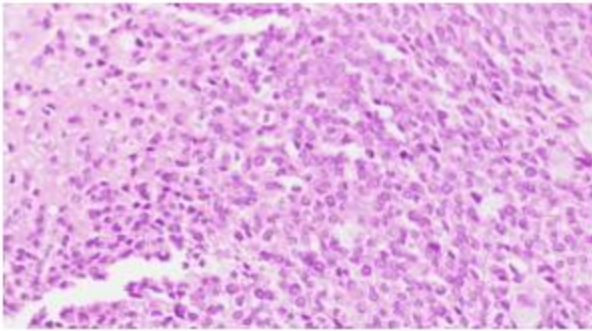


Figure 3. (B)

Figure 3 A&B: Photomicrographs (1x10 and 1x40) of histopathology specimen from polypoid ulcerated lesion at recto-sigmoid junction, 12 cm from the anal verge, showing moderately differentiated adenocarcinoma from recto-sigmoid region.

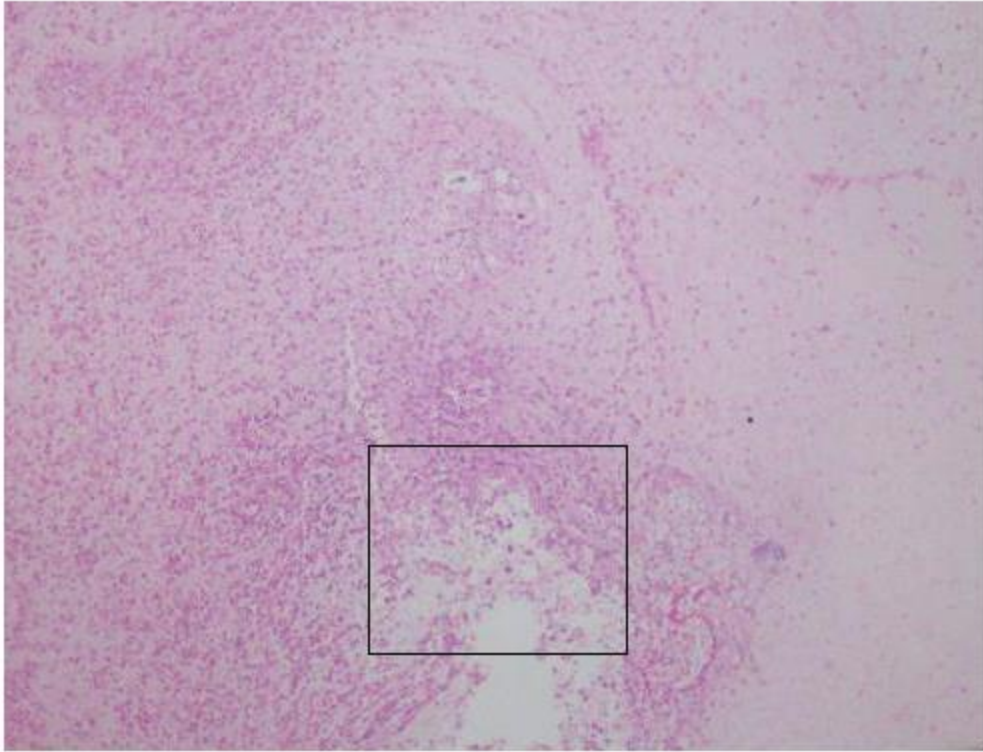


Figure 4. (A)

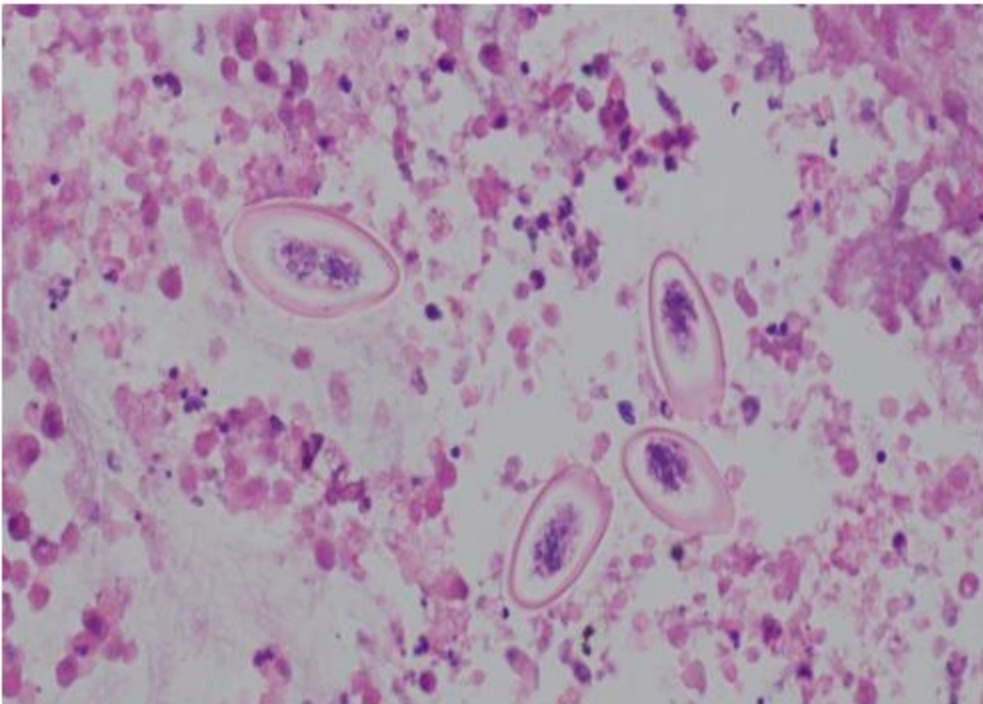


Figure 4. (B)

Figure 4 A&B. Photomicrographs (1x10 and 1x40) of histopathology specimen after LAR showing no evidence of adenocarcinoma, rather there is one focus of eosinophilic abscess, giant cell reaction and ova of *Ascaris lumbricoides*.

UNDER PEER REVIEW